



**HAL**  
open science

## Robotics and 3D modeling for precision surgery in pediatric oncology

Nicolas Vinit, Thomas Blanc, Isabelle Bloch, Luca Pio, Rani Kassir, Giammarco La Barbera, Enzo Bonnot, Pietro Gori, Jeanne Goulin, Aurore Pire, et al.

► **To cite this version:**

Nicolas Vinit, Thomas Blanc, Isabelle Bloch, Luca Pio, Rani Kassir, et al.. Robotics and 3D modeling for precision surgery in pediatric oncology. EJC Paediatric Oncology, 2024, 4, 10.1016/j.ejcped.2024.100181 . hal-04674846


**HAL Id: hal-04674846**

**<https://telecom-paris.hal.science/hal-04674846v1>**

Submitted on 21 Aug 2024

**HAL** is a multi-disciplinary open access archive for the deposit and dissemination of scientific research documents, whether they are published or not. The documents may come from teaching and research institutions in France or abroad, or from public or private research centers.

L'archive ouverte pluridisciplinaire **HAL**, est destinée au dépôt et à la diffusion de documents scientifiques de niveau recherche, publiés ou non, émanant des établissements d'enseignement et de recherche français ou étrangers, des laboratoires publics ou privés.



## Robotics and 3D modeling for precision surgery in pediatric oncology

Nicolas Vinit<sup>a,b</sup>, Thomas Blanc<sup>a,b</sup>, Isabelle Bloch<sup>c,d,e</sup>, Luca Pio<sup>d,f,g</sup>, Rani Kassir<sup>a,b,d</sup>, Giammarco La Barbera<sup>c,d</sup>, Enzo Bonnot<sup>c</sup>, Pietro Gori<sup>c</sup>, Jeanne Goulin<sup>d</sup>, Aurore Pire<sup>a</sup>, Nathalie Boddaert<sup>b,h</sup>, Cécile Lozach<sup>h</sup>, Sabine Sarnacki<sup>a,b,d,\*</sup>

<sup>a</sup> Department of Pediatric Surgery, Urology and Transplantation, Hôpital Necker-Enfants malades, AP-HP, Paris, France

<sup>b</sup> Université de Paris Cité, Paris, France

<sup>c</sup> LTCI, Télécom Paris, Institut Polytechnique de Paris, Paris, France

<sup>d</sup> IMAG2, Institut Imagine, Université de Paris Cité, Paris, France

<sup>e</sup> Sorbonne Université, CNRS, LIP6, Paris, France

<sup>f</sup> Department of Pediatric Surgery, Hôpital Bicêtre, AP-HP, Le Kremlin-Bicêtre, France

<sup>g</sup> Learning Planet Institute, Université de Paris Cité, Paris, France

<sup>h</sup> Department of Pediatric Radiology, Hôpital Necker-Enfants malades, AP-HP, Paris, France

### ARTICLE INFO

#### Keywords:

Surgical oncology  
Pediatric surgery  
Robotic surgery  
3D modeling  
Minimally invasive

### ABSTRACT

In an attempt to minimize surgical trauma in already vulnerable patients, pediatric surgeons are increasingly using minimally invasive surgery in surgical oncology, with similar outcomes as open surgery. In addition to its technical benefits, robotic surgery allows integration of technological enhancements, such as artificial-intelligence-based software or tri-dimensional (3D) modeling, into the operating room. In this article, we report our experience in robotic-assisted surgery for the resection of pediatric tumors and present current developments in 3D modeling applied to pelvic tumors. Since 2016, 149 oncology cases have been undertaken using the robotic approach. Neuroblastic tumors account for the most part, with a median hospital stay of two days [1–7 days] and very few intraoperative events. The use of robotics was mainly extended to renal tumors (predominantly Wilms tumors) and endocrine tumors, but was found of particular interest for pelvic tumors. Our experience led us to publish a first set of guidelines on robotic surgical oncology, focusing on its apparent contraindications. 3D models derived from preoperative magnetic resonance imaging have been developed for more than 150 patients with solid tumors, but the pelvic area was made a key focus because of its anatomical complexity. In addition to their educational benefits, some of these 3D models were integrated into the robotic console as a surgical aid and proved invaluable for difficult dissections or nerve plexus preservation. As evidenced by the development of robotics and 3D modeling, pediatric oncology is leaning toward ultra-precise surgical resection tailored to the patient and the tumor.

### 1. Introduction

The role and aims of surgery in the diagnosis and treatment of pediatric tumors have considerably evolved these last decades. With the development of molecular biology, tumor genetic analysis and targeted therapies, indications and requirement for resection have changed for many tumors. The will to minimize surgical burden in patients already strongly affected by cancer and delivered treatments, pushes the surgeons to use minimally invasive techniques, such as laparoscopy and thoracoscopy for pediatric cancer. With well-chosen indications and

when respecting oncological rules, the reported results, particularly in neuroblastoma [1–3] and nephroblastoma [4–6], are good in terms of morbidity and quality of resection, with EFS and OS similar to open procedures. Minimally invasive surgery (MIS) is now entering a new era with full integration of tools from interventional radiology, flexible endoscopy, robotics and integrated medical imaging. Hybrid image-guided MIS certainly appears as the next huge revolution in the surgical field but requires great technological advances including AI-based software assistance, imaging and robotics.

With patient-specific three-dimensional (3D) modeling, the surgeon

\* Corresponding author at: Department of Pediatric Surgery, Urology and Transplantation, Hôpital Necker-Enfants malades, 149 rue de Sèvres, Paris 75015, France.

E-mail address: [sabine.sarnacki@aphp.fr](mailto:sabine.sarnacki@aphp.fr) (S. Sarnacki).

<https://doi.org/10.1016/j.ejcped.2024.100181>

Received 1 May 2024; Received in revised form 15 July 2024; Accepted 18 July 2024

Available online 20 July 2024

2772-610X/© 2024 The Authors. Published by Elsevier Ltd. This is an open access article under the CC BY-NC-ND license (<http://creativecommons.org/licenses/by-nc-nd/4.0/>).

should better understand the patient's anatomy, deliver them proper counsel, predict possible complications, choose the surgical approach, and use image overlay to guide surgery with sophisticated robotic systems. While these advances have been developed for adult surgery, especially oncological surgery, pediatric oncology has not benefited from advanced simulation, computer assistance and automation. This is unfortunate, as this population requires particular attention because of small-sized critical organs and structures when compared to adults and the great need to improve postoperative course and avoid long-term morbidity.

Two major innovations: robotics and 3D imaging, are however progressively being transferred to the field of pediatric surgery and appear particularly interesting for pediatric oncology. In this article, we will report our experience in robotic-assisted surgery for the resection of pediatric tumors and present our current developments in 3D modeling applied to pelvic tumors.

## 2. Minimally invasive surgery and robotics in pediatric oncology

### 2.1. The development of minimally invasive surgery in pediatric oncology

Since the pioneer paper of Holcomb et al. [7], who reported, in 1995, a series of children with thoracic and abdominal cancer undergoing biopsy using MIS, the feasibility and accuracy of MIS for diagnostic purposes in pediatric oncological patients has been largely demonstrated [7–9]. MIS is also used for supportive care procedures such as gastrostomy [10], fertility preservation (ovarian transposition, ovarian cryopreservation) [11–13] and small bowel protection from irradiation [14].

The use of MIS for the resection of solid cancers in children has had a slower development for essentially three reasons: 1) the indications are few as most children cancers are embryonic tumors with great size at diagnosis, leaving little space in the thorax or abdomen to work, even after size reduction by neoadjuvant chemotherapy; 2) pediatric oncologists have been reluctant to such an approach for a long time, fearing incomplete resection and, most of all, peritoneal dissemination with a higher recurrence rate, as described in some adult series [15–18]; 3) pediatric surgeons historically involved in children cancer were not those who were pioneers in MIS and it took some time for both areas of expertise to merge.

Since then, however, numerous series attest the expansion of MIS for tumor resection [5,19–22]. Its well-known advantages regarding pain, recovery, and scarring have been reported, but also good oncological results, provided carefully chosen indications [23,24].

The exponential development of robotic surgery in adults [25,26] has led pediatric surgeons to also develop this approach in children. The advantages of robotic-assisted surgery over laparoscopic surgery are 3D vision, the seven degrees of freedom, tremor filtration, and precise camera control [27]. The first studies mainly concerned urological procedures [28] but today the indications extend to general surgery [29–34] and more recently to oncology [20,22,35–38]. Whereas the use of robotics in adult oncology has become commonplace [39–41], the indications in pediatric oncological surgery are still controversial (the absence of haptic feedback may increase the risk of tumor rupture) [42]. Surgical oncology in children encompasses a wide range of surgical morbidity and difficulty, from simple organ removal to large tumors with vascular involvement and adjacent-organ invasion. All these procedures should follow the oncologic principles to ensure the best possible oncologic outcome, keeping in mind that our patients have a long life ahead of them. Managing these cases calls for experienced surgeons in MIS and a solid oncological background [35,43].

In 2016, our hospital acquired a surgical robot Da Vinci Xi® (Intuitive Surgical Inc., Sunnyvale, CA, USA) and we initiated a unique robotic program dedicated to pediatrics, with a prospective study gathering now more than 600 patients. Among them, oncology accounts for 149

procedures (Fig. 1).

### 2.2. Neuroblastic tumors

Most of oncology cases have been neuroectodermic tumors (n=41) with 25 neuroblastomas (12 high risk group) and 16 ganglioneuromas or ganglioneuroblastomas. As expected, 66 % of tumors were located in the adrenal gland (n=27) and 22 % in the thorax (n=9). The robotic approach was found particularly interesting when compared to classic laparoscopy for pelvic tumors (n=5), tumors in contact or encasing the renal pedicle (n=3) or in close contact with the aorta and/or vena cava (n=2) and for rare locations like the Zuckerkandl ganglia (n=1). Thus, one third of these tumors presented image-defined risk factors (IDRFs, [44]). Tumors were usually fragmented in a bag to be taken out through a trocar opening, sometimes enlarged. There was no intraoperative event except for one conversion for a huge ganglioneuroma. Median hospital stay was two days [1–7 days]. Resection was complete, except in one case of pelvic tumor, to respect the nerve roots encased by the tumor (Fig. 2, Fig. 3). There was no local recurrence. This series helped us provide some guidelines for the respective indications for classical MIS and robotic-assisted surgery [22], thus showing that robotics allows to extend the indications of MIS in neuroblastic tumors.

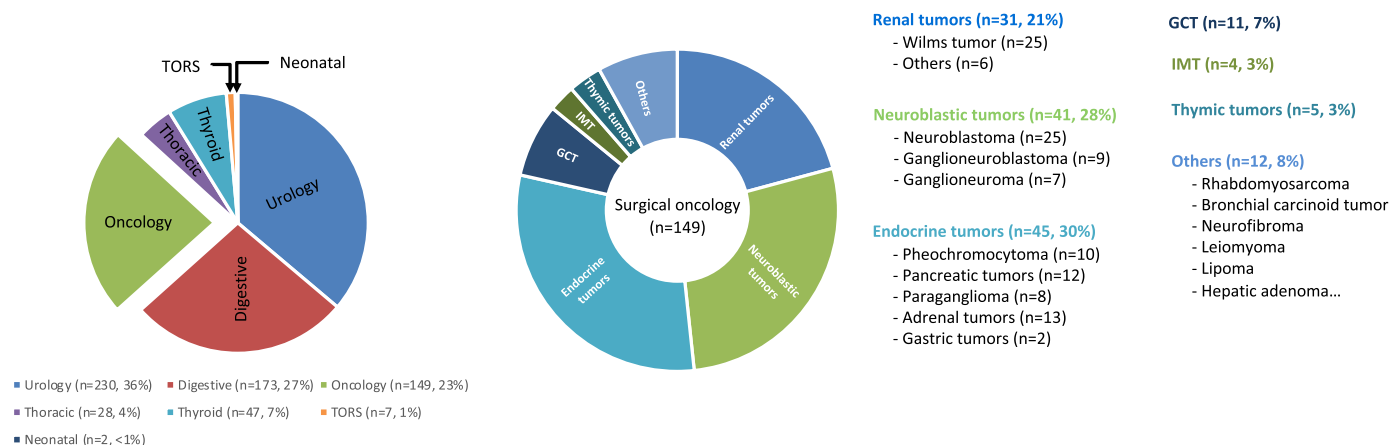
### 2.3. Kidney tumors

Regarding renal tumors, we first had to build enough robotic experience in non-tumor cases (mainly in urology, with ureteropelvic junction obstructions) and in neuroectodermic tumors (which could be fragmented), before starting applying it to kidney tumors. The preliminary results from 10 patients were reported in 2019 [19]. Total nephrectomy was done in six cases of Wilms tumor and in one case of renal sarcoma; three cases were converted. Complete tumor resection without rupture was achieved in all cases. A transperitoneal approach was used for total nephrectomy and it allowed extensive resections including spleen and diaphragm in one case. Tumors were put in a bag and taken out through a suprapubic incision. Interestingly, a retroperitoneal approach was used for nephron-sparing surgery with small tumors in three cases, including one tubulopapillary carcinoma in a previously liver-grafted patient. The aim was to preserve the peritoneal cavity for a planned re-transplantation. Mean hospital stay was four days. Neither local recurrence nor medium-term complications occurred. When compared with the open surgical approach group, median tumor volume was smaller (p=0.005), hospital stay was shorter (p=0.01), and operative time was similar (p=0.20). Since then, 17 cases of Wilms tumors have been undertaken using the robotic approach, with similar results. In one case, however, a tumor rupture occurred following conversion for poor respiratory tolerance due to a diaphragm opening, and was probably responsible for pleural recurrence two months later [22]. The patient has now completed her treatment, including radiotherapy, and is alive, free of disease with over 2 years of follow-up.

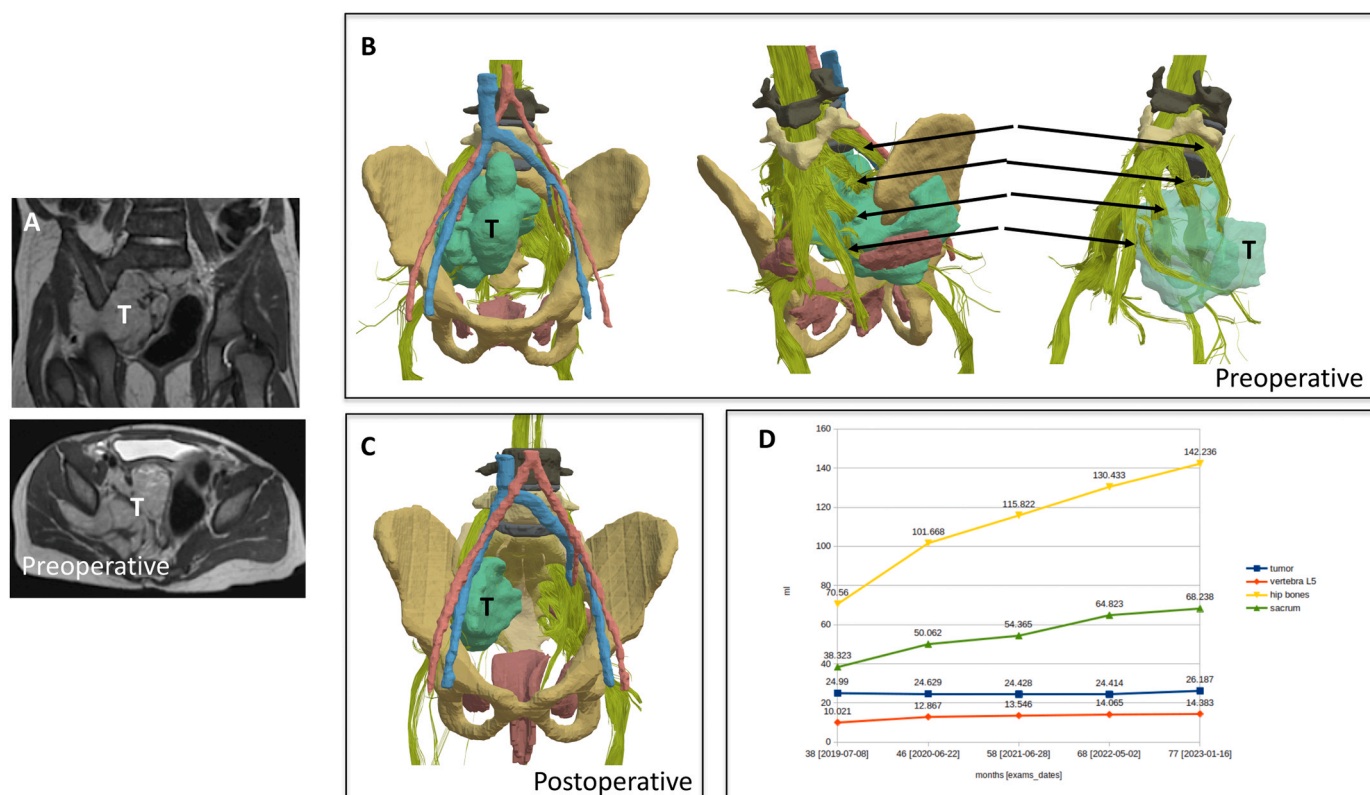
It is important to note that we did not have previous experience in conventional laparoscopic surgery for renal tumors but found that the robotic approach allowed us to reproduce exactly the different steps of an open approach.

### 2.4. Endocrine tumors

With the implementation of the robotic program, we found that endocrine pediatric tumors were good candidates for robotic-assisted surgery. There were mostly adrenal tumors with pheochromocytomas (n=10) and bilateral adrenal hyperplasia (n=13). Paragangliomas also appeared as good candidates (n=8) for this approach, as well as some pancreatic tumors like focal congenital hyperplasia (n=11) or MEN1-related pancreatic tumors (n=1). Other applications (n=12) of robotic-assisted surgery were found such as: pelvic rhabdomyosarcoma



**Fig. 1.** Robot-assisted pediatric surgical activity 2016–2024 and distribution according to tumor type within surgical oncology. TORS: Transoral robotic surgery, GCT: Germ-cell tumor, IMT: Inflammatory myofibroblastic tumor.



**Fig. 2.** A: Preoperative MRI of a right pelvic neuroblastoma (localized, non-MYC amplified) extending to the bottom in a three-year-old girl, after neoadjuvant chemotherapy (coronal and axial views). B: 3D model generated with our software. Note the encasement of L5, S1 and S3 roots (arrows). C: Postoperative 3D model of the residual tumor. D: Evolution of tumor residue volume over four years of follow-up.

(recurrence after open surgery), pelvic neurofibroma with signs of malignant transformation and some rare tumors like bronchial carcinoid tumor, abdominal leiomyoma and lipoma. No local recurrence has been reported with a follow-up of up to 5 years for some cases.

It is interesting to note that 11 % of patients in this series bore genetic predisposition syndromes, most of them belonging to the endocrine tumors group (Von Hippel Lindau, McCune Albright, Carney complex, Phox2b mutation, Gorlin syndrome...)

### 2.5. Morbidity of robotics in pediatric surgical oncology

We reported the adverse events and morbidity of our

multidisciplinary pediatric robotic surgery program with 300 consecutive cases including urology/gynecology (n=105), digestive surgery (n=83), oncology (n=66), ENT surgery (n=28) and thoracic surgery (n=18). Within the first postoperative year, 65 (22 %) children had presented with  $\geq 1$  complication, which appeared linked to the ASA score severity. Noticeably surgical oncology did not significantly increase the rate of conversion, complication, or intraoperative adverse event [30].

### 2.6. Towards the expansion of robotic surgery in pediatric oncology

The literature search recently conducted on robotic-assisted surgical





Fig. 3. Different views (from left to right: anterior, posterior, right lateral, front) of the 3D model generated from MRI scans done before surgery and postoperatively at 3 and 12 months.

oncology [35] in pediatrics yielded a total of 31 studies reporting 171 cases between 2008 and 2022, including 21 (68 %) case reports and our own published series of 93 cases. Three studies counted ten patients or more. The five most reported procedures were partial or radical adrenalectomy (41 cases), partial or radical nephrectomy (30 cases), mediastinal mass excision (17 cases), partial or radical oophorectomy (15 cases) and retroperitoneal lymph node dissection (14 cases).

The scarcity and great diversity of pediatric tumors are a serious impediment in building the large series needed to establish robotic surgery oncological guidelines.

Based on our extensive experience, we published a first set of guidelines, focusing on situations where robotic surgery is clearly contraindicated [22]. If our results show that robot-assisted surgery yields good results in pediatric oncology, two important elements must be highlighted. On the one hand, the high-volume patients load allowed for very precise choice of indications during tumor board discussions, and on the other hand, the operators' technical expertise combined with a solid knowledge of the pediatric oncologist guaranteed compliance with the oncological rules specific to each histology. Finally, it must be emphasized that economic aspects of this innovative technology are a huge hindrance to its development, as the cost of the machine and especially of the maintenance is still high. The newly-expected market competition should allow substantial cost reductions and enable widespread access to this technology.

It is worth noting that contemporary robotic systems enable the integration of complementary new technologies in pediatric surgical oncology, such as Indocyanine-green-based fluorescence-guided surgery [45]. This recent technical advancement is increasingly being applied for intraoperative guidance in pediatric solid tumors, both for vascular mapping and tumor localization [46].

### 3. 3D modeling in pediatric oncology

The very high definition 3D vision offered by the robotic camera allows us to consider the integration and, at best, an overlay of the patient's 3D imaging to obtain image-guided surgery. Advances in the processing of medical images offer the possibility to develop patient-specific 3D models designed from the segmentation of two-dimensional (2D) images, manually by contouring, or using software, integrating the automatic recognition of specific organs (3D Slicer, Myrian Studio, ITK-SNAP, etc.). Artificial intelligence (AI) techniques based on deep learning now allow quasi-automatic segmentation.

In adult abdominal surgery, 3D imaging has developed considerably in recent years, with a range of services (Visible Patient®) and software (Synapse3D®, Axial3D®), mainly dedicated to computed tomography imaging. Preliminary investigations have shown 3D-printed models of kidney tumors provide significant help compared to 2D images for the characterization, localization and understanding of kidney lesions by medical students [47,48]. Other works underline the relevance of these models in nephron-sparing surgery [49,50] but also in the understanding and acceptance of the surgical procedure by the patient and the families [51]. A few studies have evaluated the relevance of these tools in pediatric surgery, mostly in the surgery of renal tumors [52,53] or the modeling of congenital heart diseases [54,55].

These models do not usually integrate nerve imaging or nerve tractography, which is based on diffusion tensor MRI and was mainly developed in the anatomical and functional exploration of the brain but also to guide surgery of the central nervous system. Works on peripheral nerve imaging are still mostly preliminary but are highly relevant for the monitoring of nerve regeneration in preclinical models [56], the analysis of spinal dysraphism [57], pelvic tumor surgery [58] and more recently prostate surgery [59].

In this context, we developed, in collaboration with engineers, radiologists, and experts in applied mathematics, a project to obtain a 3D

representation of the pelvis, using MRI based image analysis using AI methods, and integrating visualization and modeling of the peripheral nervous system. We decided to focus on the pelvic area as this region is at the crossroad between digestive, genital, and urologic tracts, with a very rich and complex vascular and nervous network. We also wanted the model to be delivered in a timeframe compatible with its use in clinical routine. We built a dataset of 3 T MRI images acquired in the context of a research clinical protocol (n° 2015-A01705-44/2023-A02070-45) of pediatric pelvic tumors or malformations. The use of a 3 T MRI scanner allowed us to maximize the resolution of the acquisitions and, therefore, optimize 3D modeling and nerve network reconstruction. Manual segmentations were carried out for all these patients. This approach allowed us to develop automatic segmentation tools based on deep learning approaches, which today make it possible to obtain computer-assisted 3D models of bones, bladder, colon, vessels and tumors. Identification of these structures has also made possible the development of AI-based algorithms from diffusion tensor imaging sequences, to have a more efficient representation of the peripheral nerve network (lumbosacral plexus) than with the tools available on acquisition consoles and provided by manufacturers. This method integrates anatomical knowledge in the form of spatial relationships between nerves and adjacent organs to accurately identify the sacral roots of interest.

More than 150 patients have benefited from 3D models issued from their preoperative MRI and among them, 26 patients with pelvic tumors. The median age was 5 years [6 months-16 years]. There were six sacrococcygeal teratomas, nine rhabdomyosarcomas (four bladder prostate, two vagina, one urachal and two pelvic), nine neurogenic tumors (seven neuroblastomas, two ganglioneuromas) and two neurofibromas. Ten Wilms tumors have also been 3D segmented over the last five years.

Before surgery, 2D native images and 3D model were visualized by the two senior surgeons and the resident in charge of the patient. They were asked to evaluate the perception of the anatomy regarding organs, arteries, veins and tumors, the relationships between the tumor and the surrounding structures, including lumbosacral plexus, and to give their opinion regarding the reassuring effect or not of the 3D model when compared to the 2D images. During surgery, the 3D model was projected onto screens in the operating room (OR) or integrated into the consoles of the robotic system. Surgeons and residents were asked to evaluate the correlation between the expected anatomy given by the 2D and 3D models and the real observed anatomy during surgery.

Residents all agreed that the 3D model gave them a much better representation of the anatomy of the patient and helped them understand the planned surgical steps. During surgery the availability of the model on the OR screens was also perceived as a real benefit for their education. Senior surgeons found the 3D model particularly interesting for neurogenic tumors.

In this region, tumors are arising from the root itself or from the presacral sympathetic chain and are always close to or encasing the lumbosacral plexus. The visualization of the nerve network made it possible to consciously leave tumor residue around L5, S1 and S2 in two cases where these nerves were completely encased in the tumor (Fig. 2). Postoperative 3D modeling enabled us to monitor the volume of the tumor residue (Fig. 2), as well as the growth behavior of nerve axes after tumor removal (Fig. 3). Ongoing studies suggest a good correlation between patient's and observed anatomy, as well as good reproducibility of the generated model (Fig. 2, Fig. 3). We were able to observe that, despite the supervised nature (or biased by information regarding normal anatomy) of the reconstruction, the course of the lumbosacral nerves followed the deformations imposed by the tumors in some cases of pelvic neuroblastoma (Fig. 2).

During surgery, it was found reassuring to get the vision of the 3D model in the robotic console just next to the operative field for the dissection of the iliac vessels in a presacral neuroblastoma (Fig. 4) or for the dissection of a rhabdomyosarcoma recurrence infiltrating the bladder trigone (Fig. 5). We also reported a case of presacral neurofibroma resected because of signs of virulence on the positron emission tomography scan, where we could identify postoperative damage to some fibers of the S2 root with slight neurological impairment [60].

To our best knowledge, this is the first experience of 3D modeling applied to children with pelvic tumors. Whereas the benefit of 3D models is now well documented in adults but also in children [61], our procedure allows for the integration of nervous structures which we found very useful to plan and conduct pelvic surgeries.

#### 4. Conclusion

Although belated, the evolution of current trends in pediatric surgical oncology is slowly incorporating technological advancements to enhance surgical vision, increase precision and minimize surgical trauma. As evidenced by the development of robotics and 3D modeling, oncology is leaning toward ultra-precise surgical resection tailored to

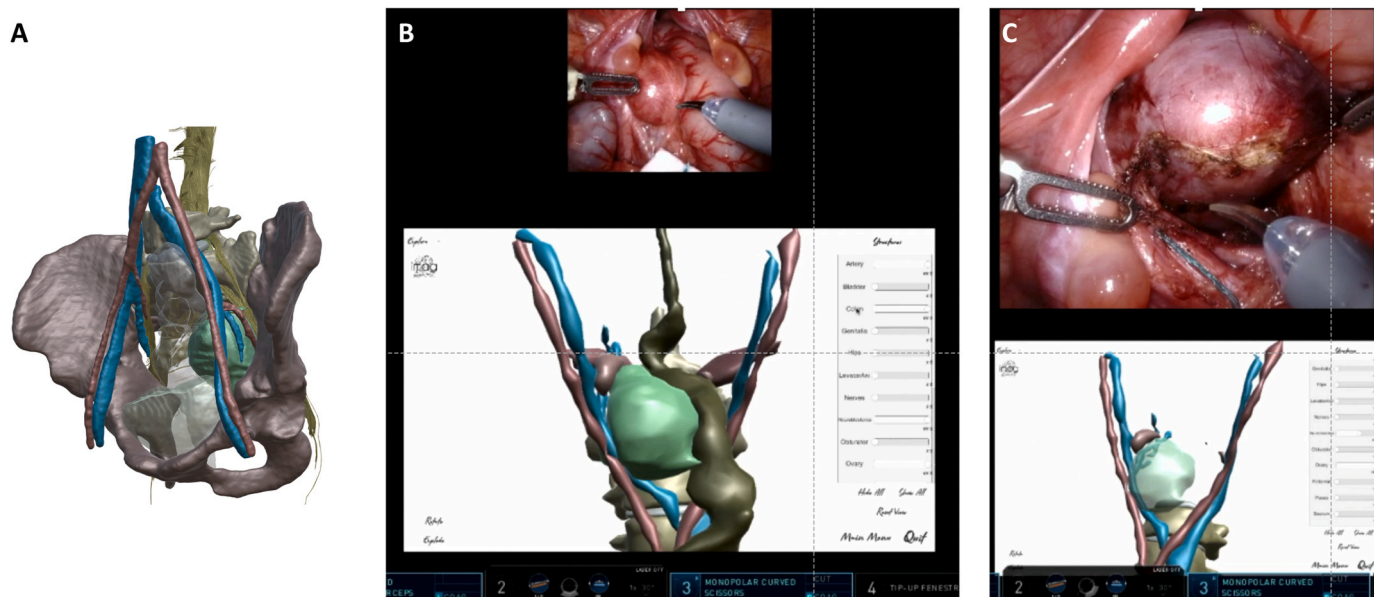
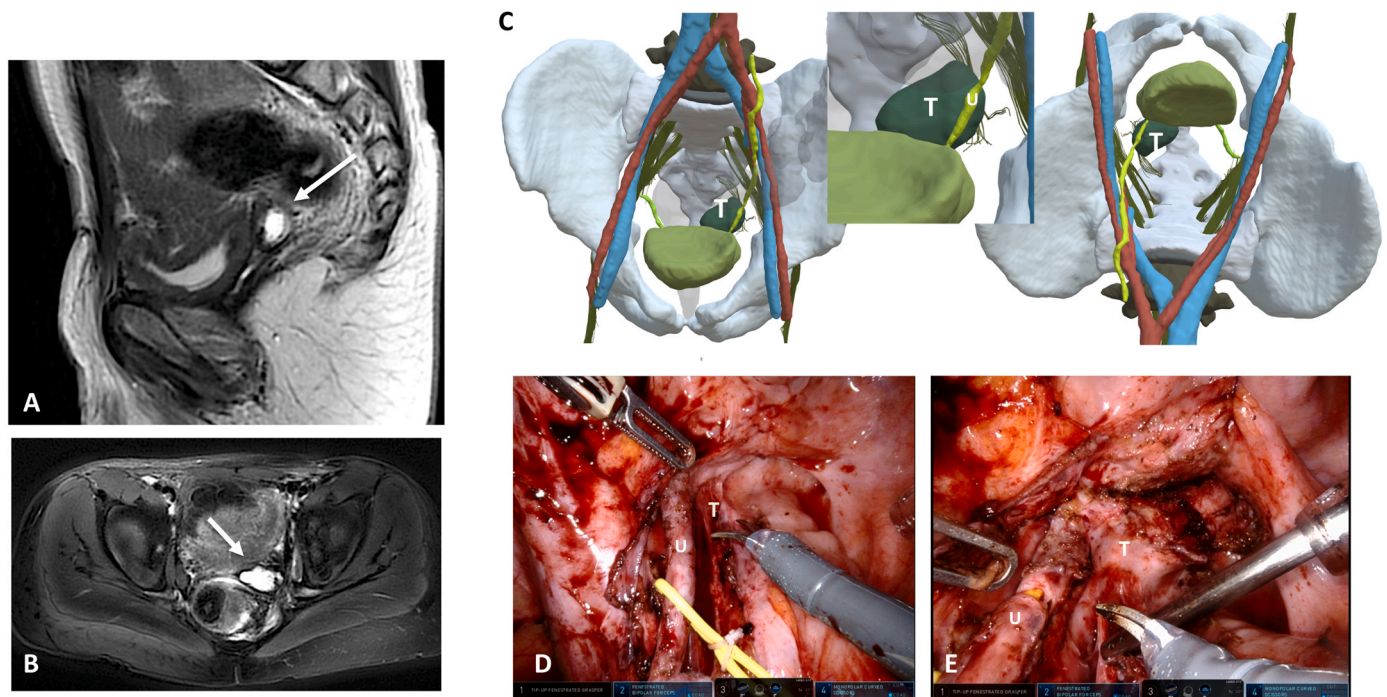


Fig. 4. Presacral neuroblastoma in a 3.5-year-old girl (A). Integration of the 3D model into the robotic console screen for surgical guidance (B, C).





**Fig. 5.** Recurrence of a pelvic rhabdomyosarcoma in a 4-year-old boy shown on preoperative MRI: sagittal (A) and axial (B) views (arrows). C: 3D model showing the left ureter (U) running onto the tumor (T). D: Intraoperative view of the dissection of the left ureter (U) from the tumor (T). E: The tumor (T) is almost resected.

the patient and the tumor. Future software enhancements allowed by the robotic console are most likely to integrate AI to increase efficiency, eradicate surgical error and improve surgical outcome.

Technological developments should, however not spread at the expense of children's safety and oncological outcome. Proper assessment of benefits and morbidity, as well as establishment of guidelines in line with the oncological principles are paramount to ensure the best possible results.

#### Funding

No specific funding was used for this manuscript.

#### CRediT authorship contribution statement

**Giammarco La Barbera:** Writing – review & editing, Data curation. **Enzo Bonnot:** Writing – review & editing, Data curation. **Pietro Gori:** Writing – review & editing, Data curation. **Jeanne Goulin:** Writing – review & editing, Data curation. **Aurore Pire:** Writing – review & editing. **Nathalie Boddaert:** Writing – review & editing, Data curation. **Cécile Lozach:** Writing – review & editing, Data curation. **Nicolas Vinit:** Writing – review & editing, Writing – original draft, Data curation. **Sabine Sarnacki:** Writing – review & editing, Writing – original draft, Validation, Supervision, Methodology, Investigation, Data curation, Conceptualization. **Thomas Blanc:** Writing – review & editing, Data curation. **Isabelle Bloch:** Writing – review & editing, Supervision, Investigation, Data curation. **Luca Pio:** Writing – review & editing, Writing – original draft. **Rani Kassir:** Writing – review & editing, Data curation.

#### Declaration of Competing Interest

The authors declare the following financial interests/personal relationships which may be considered as potential competing interests: Thomas Blanc is an official proctor for Intuitive Surgical Inc. Thomas Blanc is an official proctor for Intuitive Surgical. Sabine Sarnacki is a section editor for *European Journal of Cancer: Pediatric Oncology* and was

not involved in the editorial review or the decision to publish this article. The other authors have no conflict of interest to disclose.

#### References

- [1] M. Zenitani, M. Yoshida, S. Matsumoto, T. Sakai, R. Matsuura, S. Umeda, N. Usui, Feasibility and safety of laparoscopic tumor resection in children with abdominal neuroblastomas, *Pediatr. Surg. Int.* (2023), <https://doi.org/10.1007/s00383-023-05371-8>.
- [2] H.O. Gabra, S. Irtan, K. Cross, et al., Minimally invasive surgery for neuroblastic tumours: a SIOPEX multicentre study: proposal for guidelines, *Eur. J. Surg. Oncol.* (2022), <https://doi.org/10.1016/j.ejso.2021.08.013>.
- [3] L. Pio, A.L. Melero Pardo, T. Zaghoul, A.J. Murphy, L. Talbot, S.S. Mothi, A. M. Davidoff, A.H. Abdelhafeez, Retroperitoneoscopic or transperitoneal approach for neurogenic and adrenal tumors in children? A comparison on the way to enhanced recovery in pediatric surgical oncology, *J. Pediatr. Surg.* (2023), <https://doi.org/10.1016/j.jpedsurg.2023.06.003>.
- [4] E. Gavens, G.S. Arul, M. Pachel, A single centre matched pair series comparing minimally invasive and open surgery for the resection of pediatric renal tumours, *Surg. Oncol.* (2020), <https://doi.org/10.1016/j.suronc.2020.10.009>.
- [5] A. Bouty, T. Blanc, M.D. Leclair, et al., Minimally invasive surgery for unilateral Wilms tumors: multicenter retrospective analysis of 50 transperitoneal laparoscopic total nephrectomies, *Pediatr. Blood Cancer* (2020), <https://doi.org/10.1002/pbc.28212>.
- [6] B. Ezekian, B.R. Englum, B.C. Gulack, K.L. Rialon, J. Kim, L.J. Talbot, O.O. Adibe, J.C. Routh, E.T. Tracy, H.E. Rice, Comparing oncologic outcomes after minimally invasive and open surgery for pediatric neuroblastoma and Wilms tumor, *Pediatr. Blood Cancer* (2018), <https://doi.org/10.1002/pbc.26755>.
- [7] G.W. Holcomb, S.S. Tomita, G.M. Haase, P.W. Dillon, K.D. Newman, H. Applebaum, E.S. Wiener, Minimally invasive surgery in children with cancer, *Cancer* (1995), [https://doi.org/10.1002/1097-0142\(19950701\)76:1<121::AID-CNCR2820760119>3.0.CO;2-#](https://doi.org/10.1002/1097-0142(19950701)76:1<121::AID-CNCR2820760119>3.0.CO;2-#).
- [8] M.L. Metzelder, J.F. Kuebler, A. Shimotakahara, S. Glueer, L. Grigull, B.M. Ure, Role of diagnostic and ablative minimally invasive surgery for pediatric malignancies, *Cancer* (2007), <https://doi.org/10.1002/cncr.22696>.
- [9] J. Fuchs, The role of minimally invasive surgery in pediatric solid tumors, *Pediatr. Surg. Int.* (2015), <https://doi.org/10.1007/s00383-015-3660-9>.
- [10] I. Fernandez-Pineda, J.A. Sandoval, R.M. Jones, N. Boateng, J. Wu, B.N. Rao, A. M. Davidoff, S.J. Shochat, Gastrostomy complications in pediatric cancer patients: a retrospective single-institution review, *Pediatr. Blood Cancer* (2016), <https://doi.org/10.1002/pbc.25968>.
- [11] C.J. Harris, T.B. Lutz, E.E. Rowell, Feasibility of laparoscopic ovarian tissue cryopreservation after open abdominopelvic tumor surgery, *Am. J. Surg.* (2020), <https://doi.org/10.1016/j.amjsurg.2020.06.040>.
- [12] R. Fabbri, R. Vicenti, V. Magnani, et al., Ovarian tissue cryopreservation and transplantation: 20 years experience in Bologna University, *Front. Endocrinol. (Lausanne)* (2022), <https://doi.org/10.3389/fendo.2022.1035109>.

- [13] S. Barahmeh, M. Al Masri, O. Badran, M. Masarweh, M. El-Ghanem, I. Jaradat, I. Lataifeh, Ovarian transposition before pelvic irradiation: indications and functional outcome, *J. Obstet. Gynaecol. Res.* (2013), <https://doi.org/10.1111/jog.12096>.
- [14] S. Irtan, E. Mascard, S. Bolle, L. Brugières, S. Sarnacki, The small bowel in its hammock: how to avoid irradiation thanks to the sigmoid, *J. Laparoendosc. Adv. Surg. Tech.* (2015), <https://doi.org/10.1089/lap.2014.0270>.
- [15] A. Saini, L. Suh, J. Gao, K. Leung, G. Wilkie, K. Matteson, S. Korets, Intra-operative tumor spillage in minimally invasive surgery for endometrial cancer and its impact on recurrence risk, *Gynecol. Oncol.* (2023), <https://doi.org/10.1016/j.ygyno.2023.06.005>.
- [16] D. Dai, H. Huang, Y. Feng, T. Wan, Z. Liu, C. Tong, J. Liu, Minimally invasive surgery vs laparotomy for early stage cervical cancer: a propensity score-matched cohort study, *Cancer Med.* (2020), <https://doi.org/10.1002/cam4.3527>.
- [17] C. Fiori, E. Checcucci, D. Amparore, G. Cattaneo, M. Manfredi, F. Porpiglia, Adrenal tumours: Open surgery versus minimally invasive surgery, *Curr. Opin. Oncol.* (2020), <https://doi.org/10.1097/CCO.0000000000000594>.
- [18] J. Hoegl, D. Viveros-Carreño, T. Palacios, et al., Peritoneal carcinomatosis after minimally invasive surgery versus open radical hysterectomy: systematic review and meta-analysis, *Int. J. Gynecol. Cancer* (2022), <https://doi.org/10.1136/ijgc-2022-003937>.
- [19] T. Blanc, L. Pio, P. Clermidi, et al., Robotic-assisted laparoscopic management of renal tumors in children: preliminary results, *Pediatr. Blood Cancer* (2019), <https://doi.org/10.1002/pbc.27867>.
- [20] F. Vatta, M. Gazzaneo, M. Bertozzi, A. Raffaele, L. Avolio, G. Riccipetoni, Robotics-assisted pediatric oncology surgery—a preliminary single-center report and a systematic review of published studies, *Front. Pediatr.* (2022), <https://doi.org/10.3389/fped.2021.780830>.
- [21] J.P. Gurria, M.M. Malek, T.E. Heaton, et al., Minimally invasive surgery for abdominal and thoracic neuroblastic tumors: a systematic review by the APSA Cancer committee, *J. Pediatr. Surg.* (2020), <https://doi.org/10.1016/j.jpedsurg.2020.02.019>.
- [22] T. Blanc, P. Meignan, N. Vinit, et al., Robotic surgery in pediatric oncology: lessons learned from the first 100 tumors—a nationwide experience, *Ann. Surg. Oncol.* (2022), <https://doi.org/10.1245/s10434-021-10777-6>.
- [23] F. Varlet, T. Petit, M.D. Leclair, et al., Laparoscopic treatment of renal cancer in children: a multicentric study and review of oncologic and surgical complications, *J. Pediatr. Urol.* (2014), <https://doi.org/10.1016/j.jpurol.2013.11.005>.
- [24] K.G. McKay, M.O. Abdul Ghani, G.L. Crane, P.T. Evans, S. Zhao, L.Y. Martin, J. C. Thomas, H. Correa, D.J. Benedetti, H.N. Lovorn, Oncologic fidelity of minimally invasive surgery to resect neoadjuvant-treated wilms tumors, *Am. Surg.* (2022), <https://doi.org/10.1177/00031348211070796>.
- [25] H. Muaddi, T.A. Stukel, C. de Mestral, et al., The evolving use of robotic surgery: a population-based analysis, *Surg. Endosc.* (2023), <https://doi.org/10.1007/s00464-022-09643-7>.
- [26] K.H. Sheetz, J. Claflin, J.B. Dimick, Trends in the adoption of robotic surgery for common surgical procedures, *JAMA Netw. Open* (2020), <https://doi.org/10.1001/jamanetworkopen.2019.18911>.
- [27] T.P. Cundy, K. Shetty, J. Clark, T.P. Chang, K. Sriskandarajah, N.E. Gattas, A. Najmaldin, G.Z. Yang, A. Darzi, The first decade of robotic surgery in children, *J. Pediatr. Surg.* (2013), <https://doi.org/10.1016/j.jpedsurg.2013.01.031>.
- [28] P.P. Dangle, A. Akhavan, M. Odeleye, et al., Ninety-day perioperative complications of pediatric robotic urological surgery: a multi-institutional study, *J. Pediatr. Urol.* (2016), <https://doi.org/10.1016/j.jpurol.2015.08.015>.
- [29] T.P. Cundy, D. Di Fabrizio, N.K. Alizai, A.S. Najmaldin, Conversions in pediatric robot-assisted laparoscopic surgery, *J. Pediatr. Surg.* (2021), <https://doi.org/10.1016/j.jpedsurg.2021.10.056>.
- [30] N. Vinit, F. Vatta, A. Broch, et al., Adverse events and morbidity in a multidisciplinary pediatric robotic surgery program. A prospective, observational study, *Ann. Surg.* 278 (2023) e932–e938.
- [31] A. Alqahtani, A. Albassam, M. Zamakhshary, M. Shoukri, T. Altokhais, A. Aljazairi, A. Alzahim, M. Mallik, A. Alshehri, Robot-assisted pediatric surgery: How far can we go? *World J. Surg.* (2010) <https://doi.org/10.1007/s00268-010-0431-6>.
- [32] J.J. Meehan, A. Sandler, Pediatric robotic surgery: a single-institutional review of the first 100 consecutive cases, *Surg. Endosc. Other Inter. Tech.* (2008), <https://doi.org/10.1007/s00464-007-9418-2>.
- [33] D. Di Fabrizio, N.K. Alizai, A.S. Najmaldin, Early and long-term complications of robotic assisted laparoscopy in infants and children, *J. Pediatr. Surg.* (2023), <https://doi.org/10.1016/j.jpedsurg.2023.02.061>.
- [34] M. Saló, L. Bonnor, C. Graneli, P. Penström, M. Anderberg, Ten years of paediatric robotic surgery: lessons learned, *Int. J. Med. Robot. Comput. Assist. Surg.* (2022), <https://doi.org/10.1002/rcs.2386>.
- [35] N. Vinit, S. Sarnacki, T. Blanc, Robotic-assisted laparoscopy in pediatric surgical oncology: a narrative review, *Transl. Pediatr.* 12 (2023) 2256–2266.
- [36] W.J. Svetanoff, M. Carter, K.A. Diefenbach, M. Michalsky, D. DaJusta, E. Gong, T. B. Lautz, J.H. Aldrink, Robotic-assisted pediatric thoracic and abdominal tumor resection: an initial multi-center review, *J. Pediatr. Surg.* (2024) S0022-3468:00103-9.
- [37] J. Pu, H. Li, Y. Liu, M. Hong, S. Li, S. Tang, Robotic resection of paediatric solid tumours at a single institution, *Int. J. Med. Robot. Comput. Assist. Surg.* (2023), <https://doi.org/10.1002/rcs.2495>.
- [38] P. Li, Y. Tao, Y. Zhao, X. Lyu, X. Zhou, R. Zhuo, L. Ma, T. Tao, H. Zhou, Robotic-assisted laparoscopic surgery for the treatment of Wilms' tumor in children: single-center experience and medium-term outcomes, *J. Robot. Surg.* 18 (2024) 3.
- [39] T. Ojima, M. Nakamura, K. Hayata, et al., Short-term outcomes of robotic gastrectomy vs laparoscopic gastrectomy for patients with gastric cancer: a randomized clinical trial, *JAMA Surg.* (2021), <https://doi.org/10.1001/jamasurg.2021.3182>.
- [40] J.W.F. Catto, P. Khetrpal, F. Ricciardi, et al., Effect of robot-assisted radical cystectomy with intracorporeal urinary diversion vs open radical cystectomy on 90-day morbidity and mortality among patients with bladder cancer: a randomized clinical trial, *JAMA - J. Am. Med. Assoc.* (2022), <https://doi.org/10.1001/jama.2022.7393>.
- [41] G.D. Coughlin, J.W. Yaxley, S.K. Chambers, et al., Robot-assisted laparoscopic prostatectomy versus open radical retropubic prostatectomy: 24-month outcomes from a randomised controlled study, *Lancet Oncol.* (2018), [https://doi.org/10.1016/S1470-2045\(18\)30357-7](https://doi.org/10.1016/S1470-2045(18)30357-7).
- [42] J.J. Meehan, A.D. Sandler, Robotic resection of mediastinal masses in children, *J. Laparoendosc. Adv. Surg. Tech.* (2008), <https://doi.org/10.1089/lap.2007.0092>.
- [43] J. Fuchs, L. Schafbuch, M. Ebinger, J.F. Schäfer, G. Seitz, S.W. Warmann, Minimally invasive surgery for pediatric tumors - current state of the art, *Front. Pediatr.* (2014), <https://doi.org/10.3389/fped.2014.00048>.
- [44] S. Irtan, H.J. Brisse, V. Minard-Colin, G. Schleiermacher, S. Canale, S. Sarnacki, Minimally invasive surgery of neuroblastic tumors in children: indications depend on anatomical location and image-defined risk factors, *Pediatr. Blood Cancer* (2015), <https://doi.org/10.1002/pbc.25248>.
- [45] D. Herz, D. DaJusta, C. Ching, D. McLeod, Segmental arterial mapping during pediatric robot-assisted laparoscopic heminephrectomy: a descriptive series, *J. Pediatr. Urol.* (2016), <https://doi.org/10.1016/j.jpurol.2016.04.021>.
- [46] L. Pio, M.H.W.A. Wijnen, S. Giuliani, S. Sarnacki, A.M. Davidoff, A.A.H. Abdelhafeez, Identification of pediatric tumors intraoperatively using indocyanine green (ICG), *Ann. Surg. Oncol.* (2023), <https://doi.org/10.1245/s10434-023-13953-y>.
- [47] İ. Tatar, E. Huri, İ. Selçuk, Y.L. Moon, A. Paoluzzi, A. Skolarikos, Review of the effect of 3d medical printing and virtual reality on urology training wit' medtrain3dmodsim' erasmus + european union project, *Turk. J. Med. Sci.* (2019), <https://doi.org/10.3906/sag-1905-73>.
- [48] M. Knoedler, A.H. Feibus, A. Lange, E.M. Maddox, E. Ledet, R. Thomas, J. L. Silberstein, Individualized physical 3-dimensional kidney tumor models constructed from 3-dimensional printers result in improved trainee anatomic understanding, *Urology* (2015), <https://doi.org/10.1016/j.urology.2015.02.053>.
- [49] E. Checcucci, D. Amparore, A. Pecoraro, et al., 3D mixed reality holograms for preoperative surgical planning of nephron-sparing surgery: evaluation of surgeons' perception, *Minerva Urol. Nephrol.* (2021), <https://doi.org/10.23736/S2724-6051.19.03610-5>.
- [50] N. Wake, M.A. Bjurlin, P. Rostami, H. Chandarana, W.C. Huang, Three-dimensional printing and augmented reality: enhanced precision for robotic assisted partial nephrectomy, *Urology* (2018), <https://doi.org/10.1016/j.urology.2017.12.038>.
- [51] J.C. Bernhard, S. Isotani, T. Matsugasumi, et al., Personalized 3D printed model of kidney and tumor anatomy: a useful tool for patient education, *World J. Urol.* (2016), <https://doi.org/10.1007/s00345-015-1632-2>.
- [52] A.Y. Tsai, A.C. Greene, 3D printing in pediatric surgery, *Semin. Pediatr. Surg.* (2024), <https://doi.org/10.1016/j.sempedsurg.2024.151385>.
- [53] J.M. van der Zee, M. Fitski, F.F.J. Simonis, C.P. van de Ven, A.J. Klijn, M.H.W. A. Wijnen, A.F.W. van der Steeg, Virtual resection: a new tool for preparing for nephron-sparing surgery in wilms tumor patients, *Curr. Oncol.* (2022), <https://doi.org/10.3390/curroncol29020066>.
- [54] L. Garufi, A. Guariento, F. Bertelli, V. Vida, 3D reconstruction for a complex pediatric redo aortic arch surgery in a 9-year-old Ukrainian refugee, *Surg. Technol. Int.* 43 (2023) sti43/1738.
- [55] E.G. Milano, C. Capelli, J. Wray, B. Biffi, S. Layton, M. Lee, M. Caputo, A.M. Taylor, S. Schievano, G. Bigliani, Current and future applications of 3D printing in congenital cardiology and cardiac surgery, *Br. J. Radiol.* (2019), <https://doi.org/10.1259/bjr.20180389>.
- [56] A.F. Farinas, A.C. Pollins, M. Stephanides, et al., Diffusion tensor tractography to visualize axonal outgrowth and regeneration in a 4-cm reverse autograft sciatic nerve rabbit injury model, *Neuro. Res* (2019), <https://doi.org/10.1080/01616412.2018.1554284>.
- [57] D.V. Mehta, Magnetic resonance imaging in paediatric spinal dysraphism with comparative usefulness of various magnetic resonance sequences, *J. Clin. Diagn. Res.* (2017), <https://doi.org/10.7860/JCDR/2017/30134.10393>.
- [58] M.M. Bertrand, F. Macri, R. Mazars, S. Droupy, J.P. Beregi, M. Prudhomme, MRI-based 3D pelvic autonomous innervation: a first step towards image-guided pelvic surgery, *Eur. Radiol.* (2014), <https://doi.org/10.1007/s00330-014-3211-0>.
- [59] H. Veerman, T.N. Boellaard, J.A. van der Eijk, et al., Development and clinical applicability of MRI-based 3D prostate models in the planning of nerve-sparing robot-assisted radical prostatectomy, *J. Robot. Surg.* (2023), <https://doi.org/10.1007/s11701-022-01443-4>.
- [60] C.O. Muller, E. Mille, A. Virzi, et al., Integrating tractography in pelvic surgery: a proof of concept, *J. Pediatr. Surg. Case Rep.* (2019), <https://doi.org/10.1016/j.epsc.2019.101268>.
- [61] R. Souza, S. Ieiri, M. Uemura, et al., An augmented reality navigation system for pediatric oncologic surgery based on preoperative CT and MRI images, *J. Pediatr. Surg.* (2013), <https://doi.org/10.1016/j.jpedsurg.2013.08.025>.